West Texas Journal *of* Medicine

Case Report

# Surgical Repair of an Isolated Superior Mesenteric Vein Aneurysm: Case Report

Lauren A. Puig BS[1], Mackenzie L. Coffin BS[1], Grace E. McCrea MD[1], Edwin Onkendi MB.ChB[1,2], Mohamad Sidani, MD[1,2] Tyler J. Mouw MD[1,2]

## Abstract

We present the case of a 71-year-old female who was incidentally diagnosed with a superior mesenteric vein (SMV) aneurysm while being evaluated for lower back pain. Computed tomography (CT) imaging revealed a 3.2 cm right upper quadrant mass characterized as a saccular SMV aneurysm. Given the aneurysm size and potential risk of rupture, the patient chose to undergo elective exploratory laparotomy with tangential aneurysmectomy and primary repair. Intraoperative ultrasonography confirmed patency and flow without narrowing or thrombus formation. The patient's postoperative course was uncomplicated, and surveillance imaging at six months confirmed resolution without recurrence. This case contributes to the limited literature on VVAs and supports considering elective surgical repair for asymptomatic but anatomically significant venous aneurysms.

### Introduction

Visceral venous aneurysms (VVAs) are rare vascular malformations, with superior mesenteric vein (SMV) aneurysms accounting for approximately 8.5% of all the reported cases[1]. These lesions pose diagnostic and therapeutic challenges because of their deep anatomical location and nonspecific clinical presentation. SMV aneurysms are particularly uncommon, with a few cases documented in literature[2]. Continued case reporting remains essential to guide clinical decision-making and management in the absence of established treatment guidelines.

Patients with SMV aneurysms often present with vague abdominal symptoms, most commonly right upper quadrant (RUQ) discomfort. However, serious complications have been reported, such as gastrointestinal bleeding from rupture, portal hypertension, biliary obstruction, and thrombosis[2,3]. Physical examination is often noncontributory given the retroperitoneal location of the SMV, making imaging the primary diagnostic modality. On cross-sectional imaging, these aneurysms may present in saccular, fusiform, or diverticular forms and are often located near the splenic vein confluence[4].

### Case Presentation

A 71-year-old female with a medical history of arthritis and congenital Müllerian agenesis was referred to the surgical oncology clinic following incidental imaging findings concerning a pancreatic lesion. She was initially being evaluated for lower back pain when a lumbar spine MRI revealed a 3.4 × 3.3 cm hypointense mass-like structure in the right upper quadrant. For reference, the normal size range for the SMV is 0.4–1.3 cm[5]. Follow-up computed tomography (CT) imaging nine days later (Figure 1A-C) characterized the lesion as a 4 cm SMV aneurysm. It noted a 0.6 cm cystic area in the pancreatic body favoring a side branch intraductal papillary mucinous neoplasm (IPMN). The patient was referred to the clinic twelve weeks later, and further evaluation with CT pancreas protocol demonstrated a 3.2 cm SMV aneurysm with no evidence of pancreatic lesions or ductal dilatation (Figure 1D-F).

At her initial surgical oncology clinic visit four

**Corresponding Author:**
Tyler Mouw MD,
Texas Tech University Health Sciences Center – Division of Surgical Oncology, Department of Surgery
Lubbock, Texas
Email Address: tyler.mouw@ttuhsc.edu

days after the CT with pancreas protocol, the patient was asymptomatic, with no reported abdominal pain, gastrointestinal symptoms, weight loss, or constitutional symptoms. She also had no medical history of gastrointestinal bleeding, portal hypertension, liver disease, pancreatitis, or abdominal trauma.

The initial plan was for observation with repeat imaging within six months. However, after the case was reviewed at the hepatobiliary multidisciplinary conference, concerns about the lesion's size and potential risk of rupture prompted a decision to offer the patient surgical repair. After discussion with the patient, they elected to proceed with surgical repair.

After approximately seven months from initial presentation, the patient underwent exploratory laparotomy with aneurysmectomy of the proximal SMV and primary venous repair. Intraoperatively, a 3 cm saccular aneurysm was found at the proximal SMV, closely associated with the superior mesenteric artery, which was successfully dissected (Figure 2A). Intraoperative Doppler ultrasound confirmed aneurysmal dilation and preserved venous flow (Figure 2B). The aneurysm was then isolated using a Satinsky clamp (Figure 2C), excised via tangential aneurysmectomy, and the resulting venous defect was closed primarily with a 5-0 Prolene suture (Figure 2D).

Her postoperative course was notable for a decrease in hemoglobin from 11.0 g/dL on postoperative day one to 7.3 g/dL on day two, which was managed with transfusion of two units of packed red blood cells. A CT angiogram of the abdomen and pelvis revealed a small hematoma within the anterior abdominal wall and a large subcapsular hematoma of the liver, without evidence of active extravasation. A hypodense lesion in the pancreatic head and uncinate process, corresponding to the previously identified small cystic lesion, was again visualized but showed no enhancement, suggesting residual blood flow. The remainder of her recovery was uneventful, and she was discharged in stable condition on postoperative day five.

At her postoperative six-month follow-up, the patient remained asymptomatic. Repeat CT of the abdomen/pelvis with liver protocol showed complete resolution of the aneurysm. Vessel caliber was normal; no evidence of recurrence was observed. She is currently undergoing surveillance imaging every six months.

## Discussion

A 3.2 cm SMV aneurysm was incidentally discovered in a 71-year-old female during an evaluation for lower back pain. Despite being asymptomatic and lacking risk factors, such as portal hypertension, liver disease, pancreatitis, or abdominal trauma, she underwent elective aneurysmectomy with primary repair due to concern for rupture. Her postoperative course

was notable for a hepatic subcapsular hematoma and hemoglobin drop requiring transfusion; however, she recovered uneventfully and remained asymptomatic, with complete resolution of the aneurysm on follow-up imaging seven months postoperatively.

Although VVAs are rare, those involving the SMV are particularly uncommon. A 2009 systematic review identified 176 patients with 198 VVAs across 93 case reports, with only 17 (8.5%) localized to the SMV[1]. More recent data suggest an even lower frequency, with SMV involvement accounting for 4.83% of all portal venous aneurysms[6]. The most common locations for VVAs are within the portal venous system, including the extrahepatic portal vein, splenic vein, and splenic-SMV confluence[1].

Patient presentation of VVAs varies widely and is often nonspecific. In the same 2009 review, 44.7% of patients reported abdominal pain, while gastrointestinal bleeding occurred in 7.3%[1]. Notably, 38.2% of the cases were entirely asymptomatic and identified incidentally during imaging, consistent with our patient's presentation[1]. Back pain on presentation was attributed to a musculoskeletal origin. Because of their retroperitoneal location, SMV aneurysms are typically difficult to detect on physical examination, emphasizing the importance of cross-sectional imaging. Morphologically, VVAs may appear as saccular, fusiform, or diverticular. In our case, the aneurysm exhibited a saccular configuration, with focal dilation of the SMV in a single direction (Figure 2A).

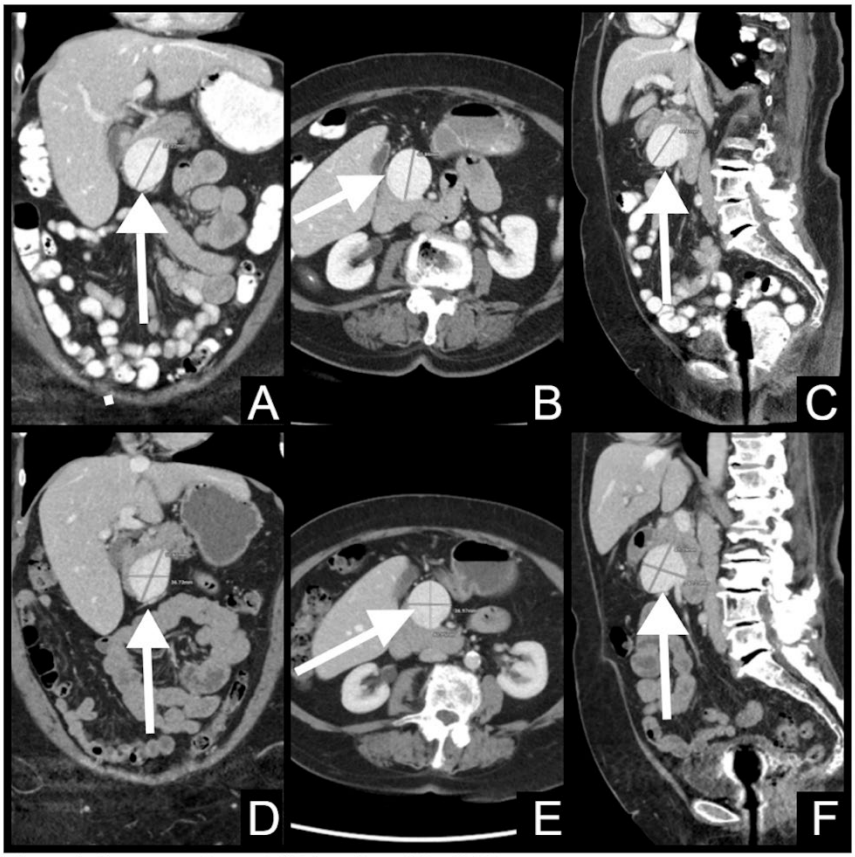


**Figure 1**: **Contrast-enhanced CT imaging of the SMV aneurysm.**
**(A-C)** Initial CT: Coronal **(A)**, axial **(B)**, and sagittal **(C)** views showing a 4.0 cm saccular aneurysm at the junction of the middle colic vein. **(D-F)** Subsequent 12-week pancreatic protocol CT: Coronal **(D)**, axial **(E)**, and sagittal **(F)** views demonstrating interval size reduction to 3.2 cm.

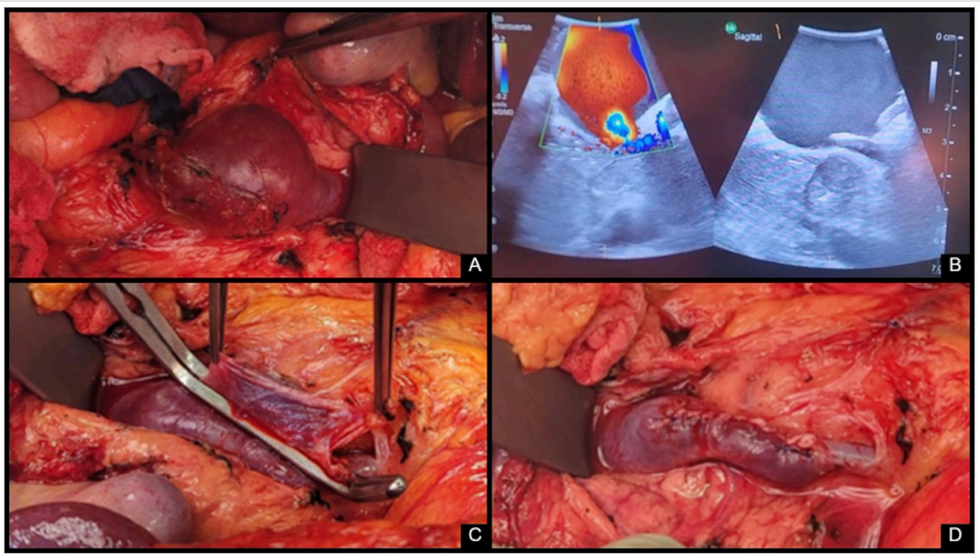


**Figure 2: Intraoperative Photos and Ultrasound.**
**(A)** Intraoperative view of the superior mesenteric vein (SMV) aneurysm before resection, measuring approximately 3.2 cm in diameter. **(B)** Intraoperative Doppler ultrasound confirming aneurysmal dilation and preserved venous flow. **(C)** Satinsky clamp applied across the SMV to facilitate tangential aneurysmectomy. **(D)** Completed primary closure of the SMV following aneurysm resection, demonstrating intact vessel continuity.

The etiology of VVAs remains incompletely understood but is broadly categorized as acquired or congenital. Acquired causes are more common and include portal hypertension, cirrhosis, pancreatitis, trauma, or prior abdominal surgery[7]. However, our patient did not exhibit any of these risk factors. This supports a congenital etiology, possibly linked to embryologic vascular anomalies. One proposed theory suggests that incomplete regression of the caudal segment of the right vitelline vein can result in a small diverticulum at the caudal-ventral intervitelline anastomosis, which may enlarge over time and evolve into an aneurysm[2,3].

The decision to proceed with elective surgical repair was based on the aneurysm size and concern for rupture. Laurenzi et al. noted that in patients without portal hypertension, saccular or fusiform aneurysms can be treated with aneurysmorrhaphy or aneurysmectomy[7]. In contrast, patients with portal hypertension often require decompressive shunt procedures or liver transplantation in advanced cases[7].

Conservative management with imaging surveillance is sometimes appropriate for small, asymptomatic lesions; larger aneurysms (> 3 cm) and those with evidence of mural thrombus are considered for intervention due to the risk of rupture, compression of surrounding structures, or complications of thrombosis[7,8]. In patients with thrombosed aneurysms, anticoagulation can also be considered to prevent embolization[6].

In this case, the patient's asymptomatic but anatomically significant SMV aneurysm, greater than 3 cm in size and located adjacent to the superior mesenteric artery, was reviewed at a hepatobiliary multidisciplinary conference. Consensus favored operative management, given the risk of rupture and thrombosis. The patient underwent tangential aneurysmectomy with primary repair, a technique that maintains venous continuity without the need for grafting.

Postoperative bleeding and hepatic subcapsular hematoma, while concerning, were conservatively managed. The absence of active extravasation and the patient's clinical stability supported non-operative management.

Resolution of the aneurysm with preserved vessel patency on follow-up imaging confirmed the success of the procedure (Figure 3A-C).

Despite the favorable outcomes, this case highlights several limitations in the current VVA management. The rarity of SMV aneurysms makes it difficult to establish evidence-based protocols, and treatment decisions must rely heavily on individual patient factors and surgeon

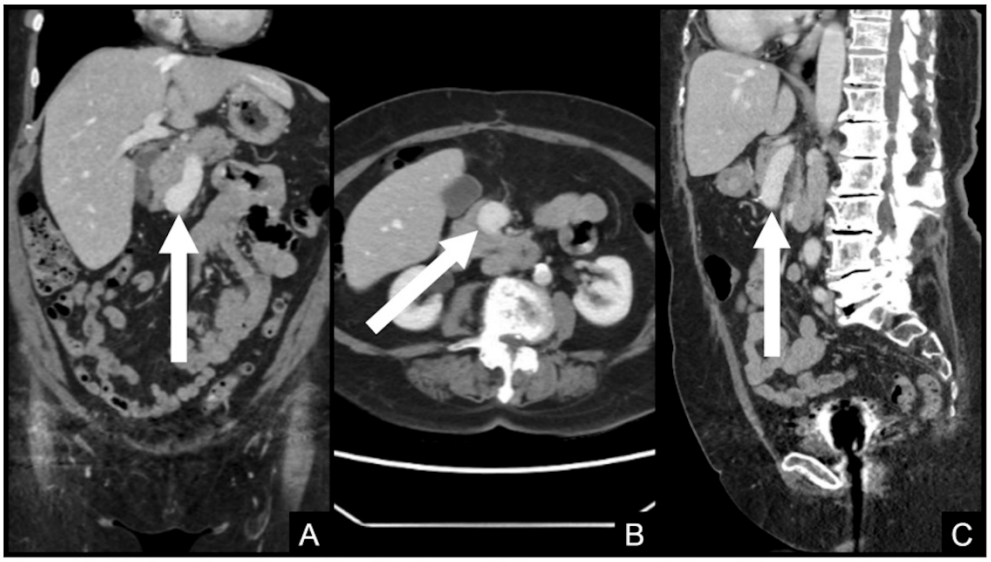


**Figure 3: CT imaging 12 months after tangential aneurysmectomy of the complete resolution of the SMV aneurysm.**

**(A)** Coronal, **(B)** axial, and **(C)** sagittal views showing a patent superior mesenteric vein with preserved vessel caliber at the repair site. No evidence of aneurysm recurrence, stenosis, or thrombosis.

experience. Additionally, the long-term durability of the repair remains unknown, as our current follow-up period extends only to seven months. Furthermore, because this patient underwent surgical intervention, our report does not provide insight into the conservative management of SMV aneurysms.

**Conclusions** SMV aneurysms are rare and potentially life-threatening. Although often clinically silent, complications such as thrombosis and rupture may develop without warning. Early detection through imaging, multidisciplinary evaluation, and appropriate surgical planning can lead to excellent outcomes. This case adds to the limited body of literature supporting tangential aneurysmectomy with primary repair as a safe and effective strategy for selecting patients with anatomically significant, asymptomatic SMV aneurysms.

**References**

1. Sfyroeras GS, Antoniou GA, Drakou AA, Karathanos C, Giannoukas AD. Visceral venous aneurysms: clinical presentation, natural history and their management: a systematic review. *Eur J Vasc Endovasc Surg Off J Eur Soc Vasc Surg*. 2009;38(4):498-505. doi:10.1016/j.ejvs.2009.05.016

2. Nitesh P, Biju P, Kalayarasan R. Superior Mesenteric Vein Aneurysm With Arteriovenous Communication and Portal Vein Thrombosis: A Rare Presentation in Non-cirrhotic Portal Hypertension. *Cureus*. 2023;15(7):e42595. doi:10.7759/cureus.42595

3. Carneiro C, Brito J, Bilreiro C, et al. All about portal vein: a pictorial display to anatomy, variants and physiopathology. *Insights Imaging*. 2019;10(1):38. doi:10.1186/s13244-019-0716-8

4. Wolosker N, Zerati AE, Nishinari K, de Melo Galvão Filho M, Wolosker AMB. Aneurysm of superior mesenteric vein: case report with 5-year follow-up and review of the literature. *J Vasc Surg*. 2004;39(2):459-461. doi:10.1016/j.jvs.2003.08.008

5. Lechowicz R, Elwertowski M. Standards of the Polish Ultrasound Society. Ultrasound examination of the portal system and hepatic vessels. *J Ultrason*. 2015;15(61):208-226. doi:10.15557/JoU.2015.0018

6. Kurtcehajic A, Zerem E, Alibegovic E, Kunosic S, Hujdurovic A, Fejzic JA. Portal vein aneurysm-etiology, multimodal imaging and current management. *World J Clin Cases*. 2023;11(4):725-737. doi:10.12998/wjcc.v11.i4.725

7. Laurenzi A, Ettorre GM, Lionetti R, Meniconi RL, Colasanti M, Vennarecci G. Portal vein aneurysm: What to know. *Dig Liver Dis Off J Ital Soc Gastroenterol Ital Assoc Study Liver*. 2015;47(11):918-923. doi:10.1016/j.dld.2015.06.003

8. Moreno JA, Fleming MD, Farnell MB, Gloviczki P. Extrahepatic portal vein aneurysm. *J Vasc Surg*. 2011;54(1):225-226. doi:10.1016/j.jvs.2010.05.113

**Affiliations:**
[1] Texas Tech University Health Sciences Center - School of Medicine
[2] Texas Tech University Health Sciences Center – Division of Surgical Oncology, Department of Surgery